Sigmoid Volvulus Complicated by Megacolon and Gangrene in a 50-Year-Old Female – Case Report

Dr. Rushikesh Yadav[1*], Dr. Ravina Kodalkar[1], Dr Roshan Patil[2]
[1]Junior resident, [2]Assistant professor
Department of General Surgery, Vedantaa institute of medical sciences, Dahanu, Maharashtra.

*Corresponding author
Dr. Rushikesh Yadav
Junior Resident, Department of General Surgery, Vedantaa Institute of Medical Sciences, Dahanu, Maharashtra
Email :- rushikeshyadav44@gmail.com

ABSTRACT

A 50-year-old female presented with diffuse abdominal pain for 4 days, sudden-onset colicky pain, progressive distension, and complete obstipation. She experienced 2--3 episodes of non-bilious, non-projectile vomiting the day prior to admission. No history of trauma or prior surgeries was reported. Physical exam revealed distension, diffuse tenderness with guarding and rigidity, and absent bowel sounds. Plain abdominal X-ray demonstrated multiple air-fluid levels and gross colonic dilatation. Ultrasound suggested an overdistended gallbladder and pelvic fluid, with sluggish intestinal peristalsis. Contrast-enhanced CT scan showed massive sigmoid dilatation (maximum transverse diameter 7.5 cm) with an abrupt cut-off at the distal rectosigmoid junction and collapse of the rectum, raising suspicion for sigmoid volvulus with vascular compromise. A provisional diagnosis of sigmoid volvulus with megacolon was made. Emergency exploratory laparotomy revealed sigmoid volvulus with mesenteric ischemia and gangrene extending proximally into the upper rectum; the colon was dilated approximately 10--12 cm. No perforation was identified. Resection of the gangrenous sigmoid and proximal rectum was performed, and a Hartmann's procedure constructed.
Post-operatively, the patient was managed in ICU with intravenous fluids and broad-spectrum antibiotics. The course was uneventful. This case highlights the importance of prompt radiological diagnosis and timely surgical intervention in sigmoid volvulus with megacolon and gangrene.

Keywords: sigmoid volvulus; megacolon; Hartmann's procedure; bowel obstruction; abdominal pain.

INTRODUCTION

Sigmoid volvulus---torsion of the sigmoid colon around its mesentery---is a significant cause of large bowel obstruction in India and other "volvulus belt" regions due to high-fibre diets and redundant colon anatomy. When complicated by megacolon and ischemia, it carries high morbidity and mortality. We report such a case in a 50-year-old woman, emphasizing the radiological, intra-operative, and management aspects

> ***Take Home Message***
> Delayed presentation and diagnosis of sigmoid volvulus can result in severe complications such as megacolon and gangrene. This case reinforces the need for timely referral, early imaging, and decisive surgical treatment in suspected cases.

CASE REPORT

History & Examination

A 50-year-old woman presented to casualty with 4 days of diffuse abdominal pain progressing to colicky pain, associated with distension and inability to pass stool or flatus. She reported 2--3 episodes of non-bilious, non-projectile vomiting the day before admission. There was no trauma or prior surgeries, nor any significant medical history. On examination, the bowel sounds were absent. Per-rectal examination revealed a normal, roomy anal verge; the patient was in distress. Vital signs: BP 100/70 mmHg, pulse 110 bpm. The abdomen was distended, moderately tender in all quadrants with guarding and rigidity.

Investigations

Chest X-ray: Bilateral lung fields appear clear with no evidence of pneumoperitoneum or cardiopulmonary complications.

Figure 1: Chest X-ray (PA view) showing clear bilateral lung

fields with no evidence of free air under the diaphragm, ruling out perforation. The cardiac silhouette appears normal **Plain abdominal radiograph:** Multiple air-fluid levels and massive colonic dilatation.

Figure 2: Plain abdominal X-ray demonstrating massive colonic dilatation with multiple air-fluid levels, characteristic of large bowel obstruction. The grossly distended colon can be seen throughout the abdomen.

Ultrasound: Overdistended gallbladder; mild pelvic fluid; sluggish bowel peristalsis.
CECT abdomen/pelvis: Gross sigmoid dilatation (≈7.5 cm transverse diameter), abrupt
cut-off at distal recto-sigmoid junction; collapsed rectum (consistent with sigmoid volvulus ± compromised vascularity).

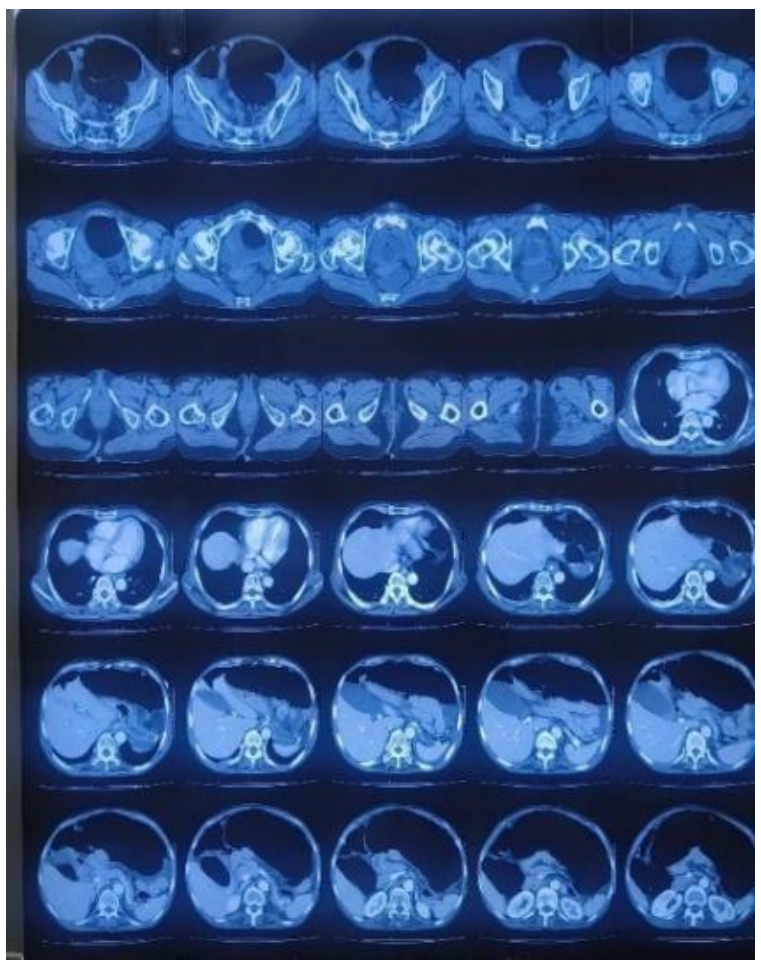

Figure 3: CECT abdomen showing multiple axial sections through the upper abdomen and thorax, demonstrating the extent of colonic dilatation and associated findings.

Provisional Diagnosis

Sigmoid volvulus with megacolon and possible compromise of vascularity.

Surgical Procedure & Intra-operative Findings: At exploratory laparotomy, a twisted sigmoid colon was found with mesenteric ischemia and gangrenous changes extending into the proximal rectum. The sigmoid colon was grossly
dilated (approx. 10--12 cm) but there was no perforation. The gangrenous segment was excised, including the distal sigmoid and proximal rectum, and an end colostomy was fashioned (Hartmann's procedure).

Figure 4: Intraoperative photograph showing the massively dilated and gangrenous sigmoid colon in situ. The characteristic dark, dusky appearance of the bowel wall with areas of hemorrhage and necrosis clearly demonstrates the extent of vascular compromise requiring surgical resection.

Figure 5: The resected gangrenous sigmoid colon specimen showing the characteristic dark, necrotic appearance with areas of hemorrhage and tissue death. The specimen demonstrates the extensive nature of the vascular compromise that necessitated surgical resection.

Postoperative Management

The patient was transferred to ICU, managed with IV fluids, broad-spectrum antibiotics, regular monitoring of vitals, and stoma care. She remained hemodynamically stable, tolerated oral intake following ileus resolution, and was discharged in good condition.

DISCUSSION

Sigmoid volvulus often presents with abdominal pain, distension, obstipation, and late vomiting. CT imaging reliably identifies the whirl sign, colonic dilatation, and transition point, aiding diagnosis. In megacolon-associated volvulus, recurrence rates and complications increase significantly, particularly if gangrene is present. Hartmann's procedure remains the preferred operation when gangrene is identified and conditions are unfavorable for primary anastomosis. Elective sigmoid colectomy is recommended following successful non-operative decompression in viable bowel cases. This case echoes findings from
previously reported cases with similar presentations. The anatomical and geographical predisposition (South Asia) may explain incidence in this region.

CONCLUSION

Sigmoid volvulus complicated by megacolon and gangrene is a surgical emergency requiring prompt imaging and operative intervention. Hartmann's procedure is appropriate in gangrenous disease. Awareness and timely management can markedly reduce morbidity

.

ACKNOWLEDGEMENT

We thank the surgical team and ICU staff for their contributions in patient care.

REFERENCES

1. Atamanalp, S. S. (2013). Treatment of sigmoid volvulus: a single-center experience of 952 patients over 46.5 years. Techniques in Coloproctology, 17, 561--569.
2. Lee, S.-H., Ahn, B.-K., & Baek, S.-U. (2015). Volvulus of the sigmoid colon associated with rectal cancer: A case report. Gastroenterology Research, 8(1), 160-- 162.
3. Ryan, P. (1982). Sigmoid volvulus with and without megacolon. [Journal].
4. Bhat, S. (Ed.). SRB's Manual of Surgery. JP Medical Ltd.
5. Chung, Y. F., Eu, K. W., Nyam, D. C., Leong, A. F., Ho, Y. H., & Seow-Choen, F. (1999). Minimizing recurrence after sigmoid volvulus. British Journal of Surgery, 86(2), 231--233.